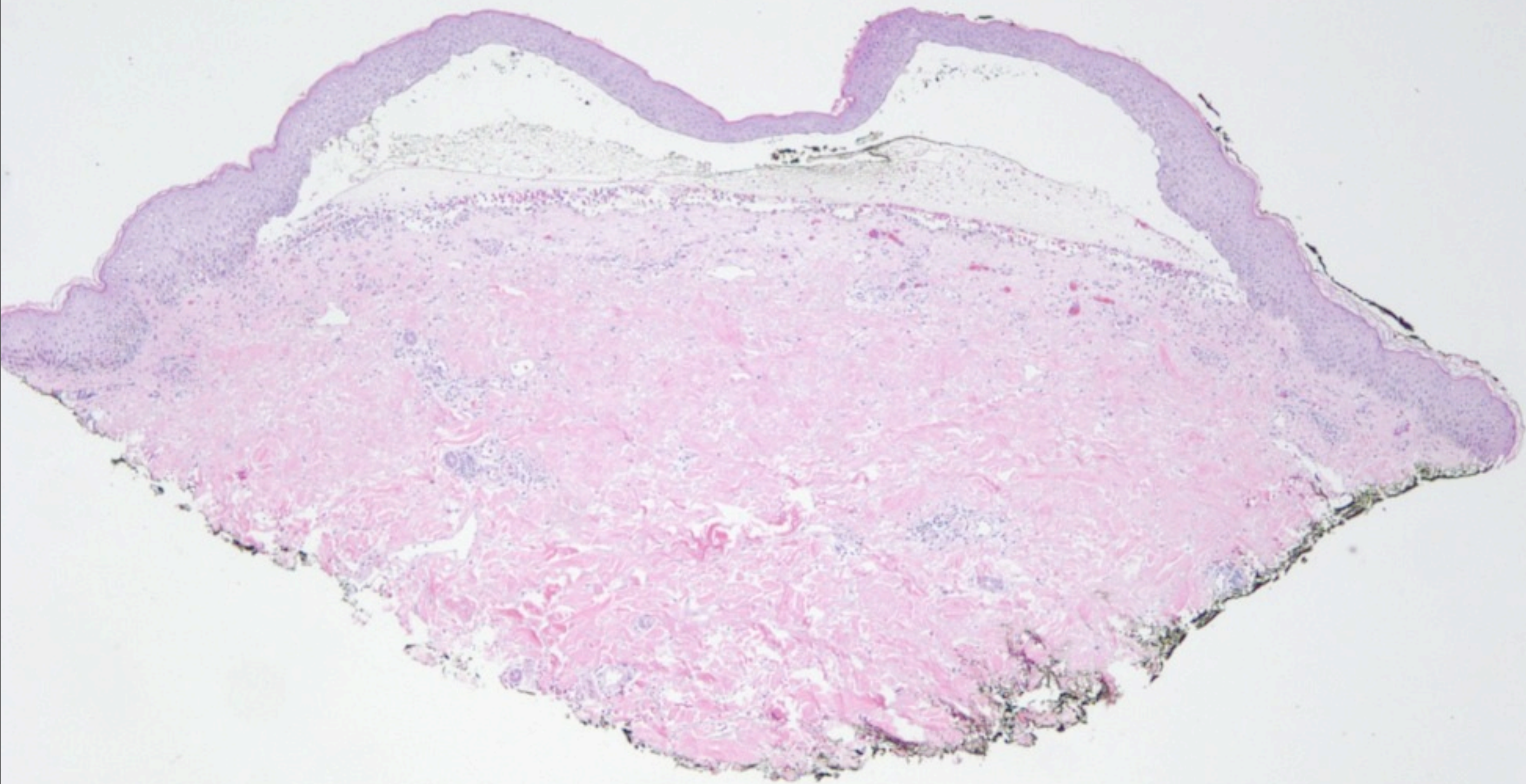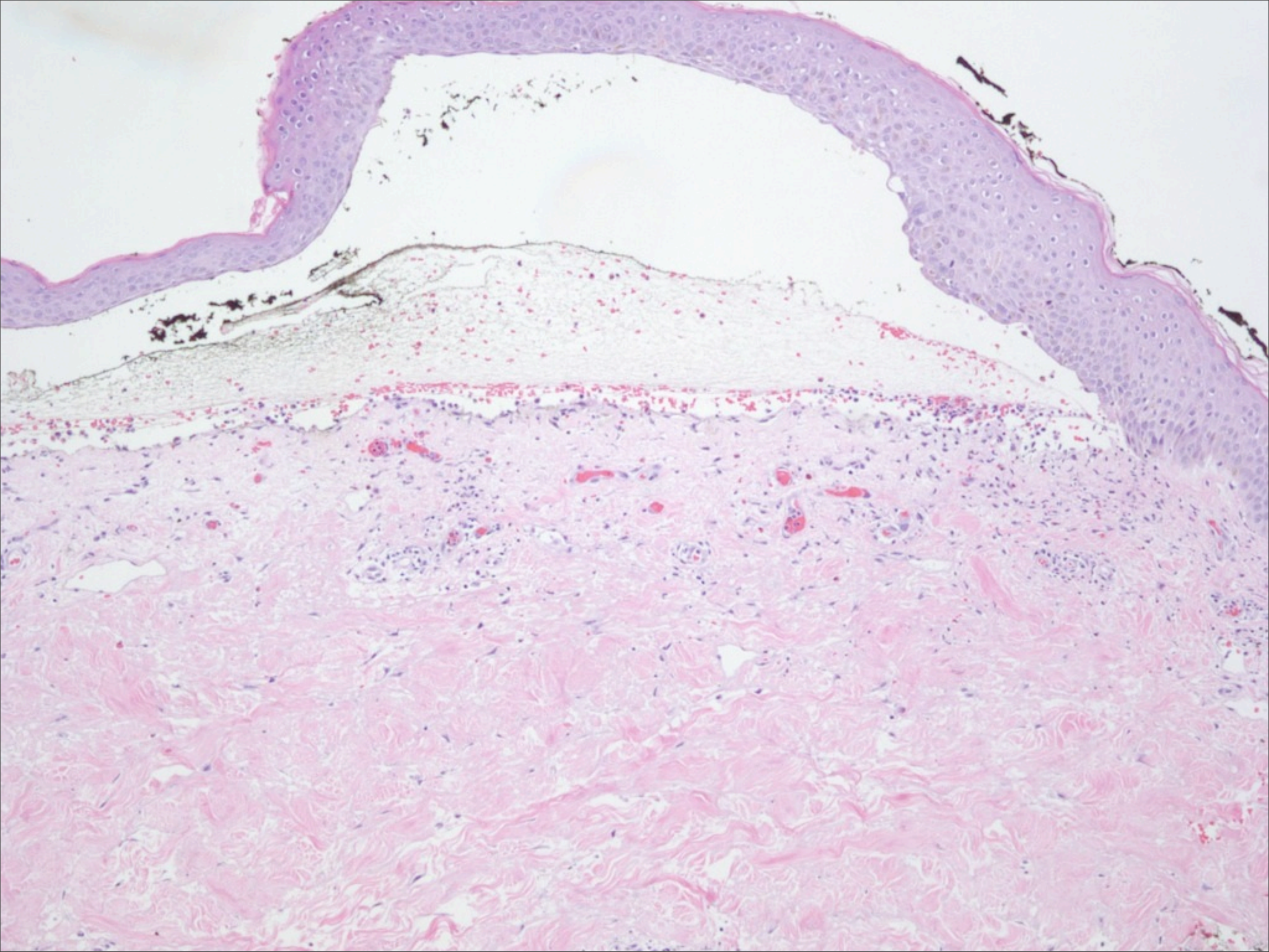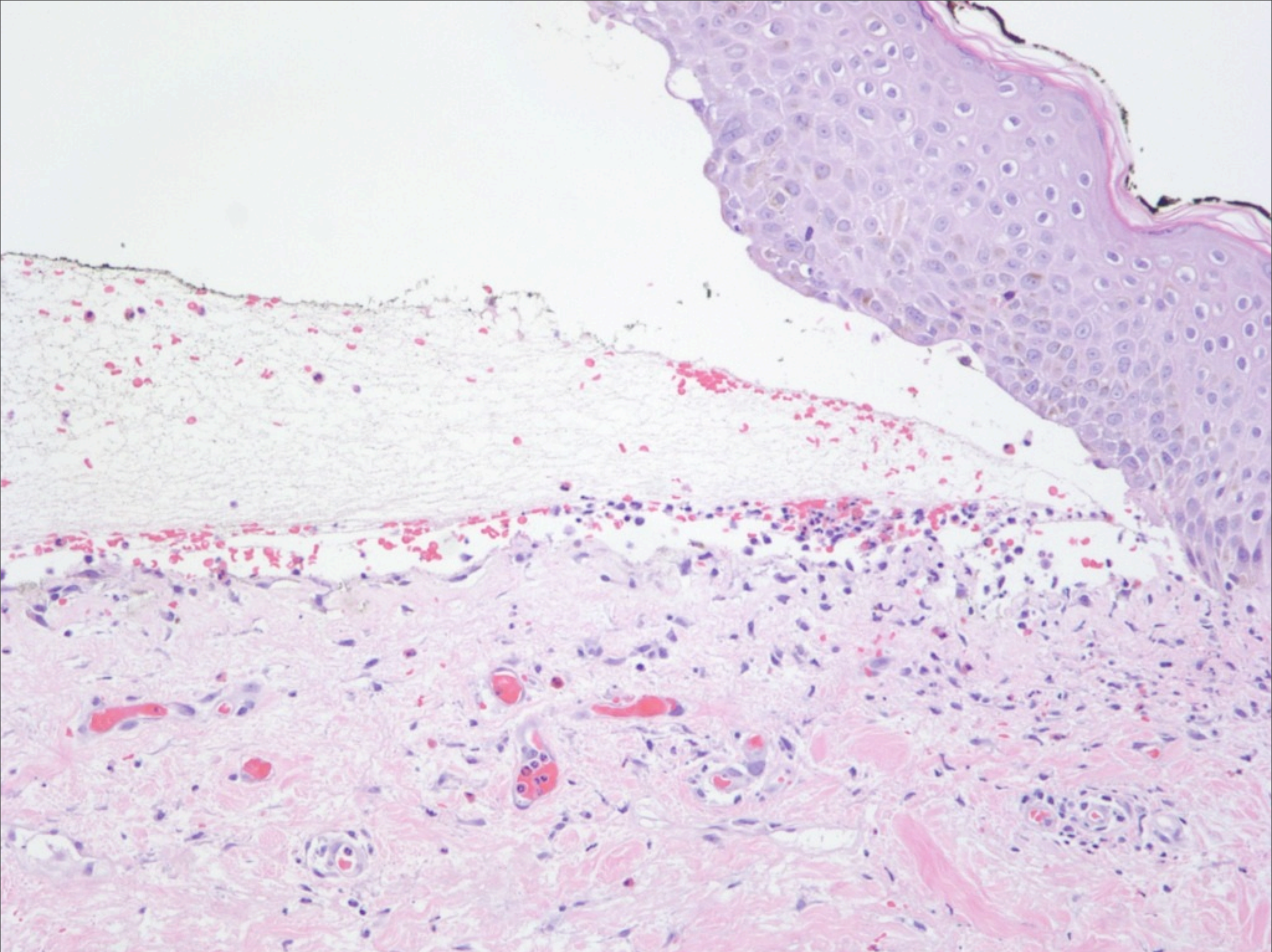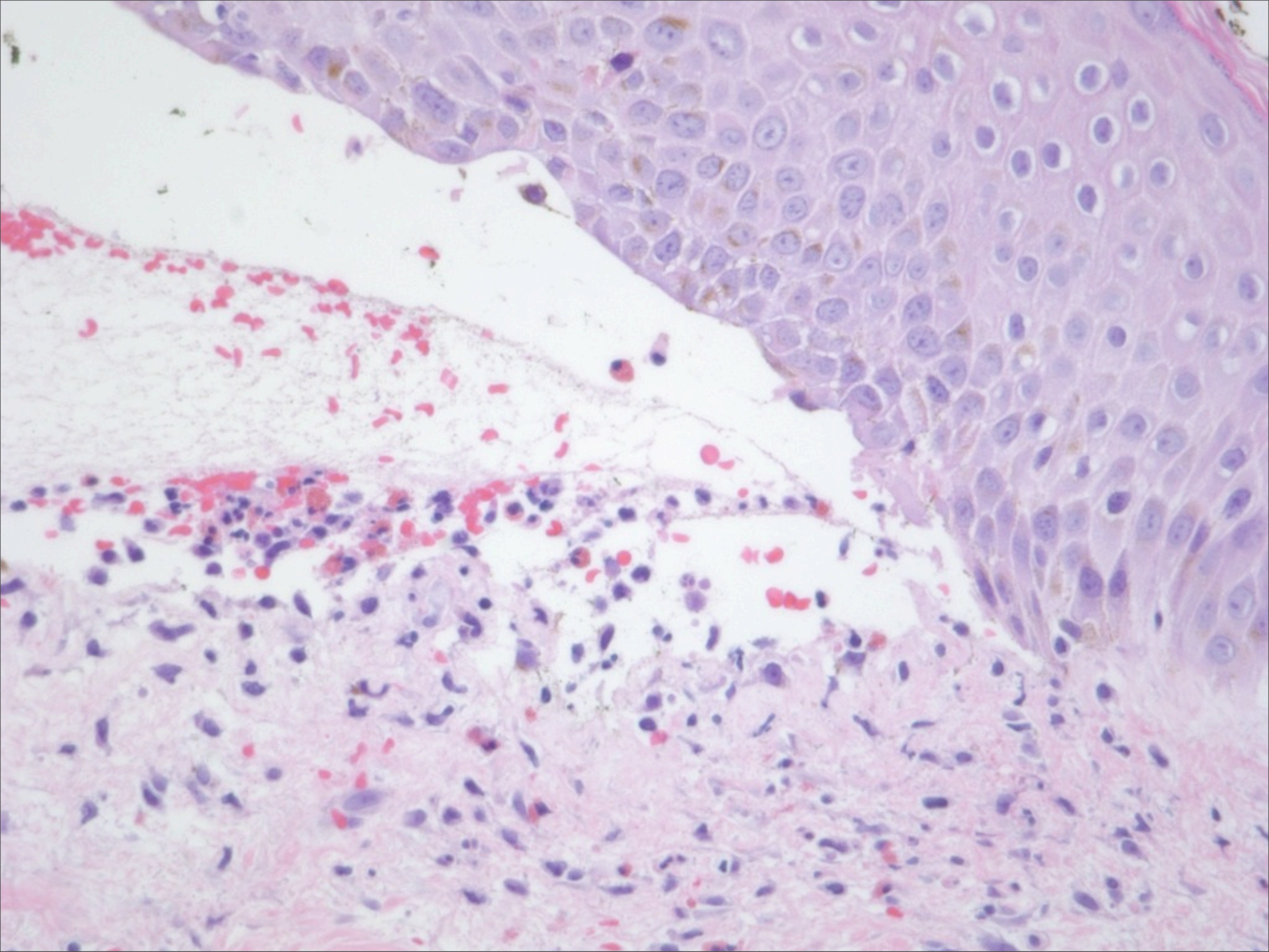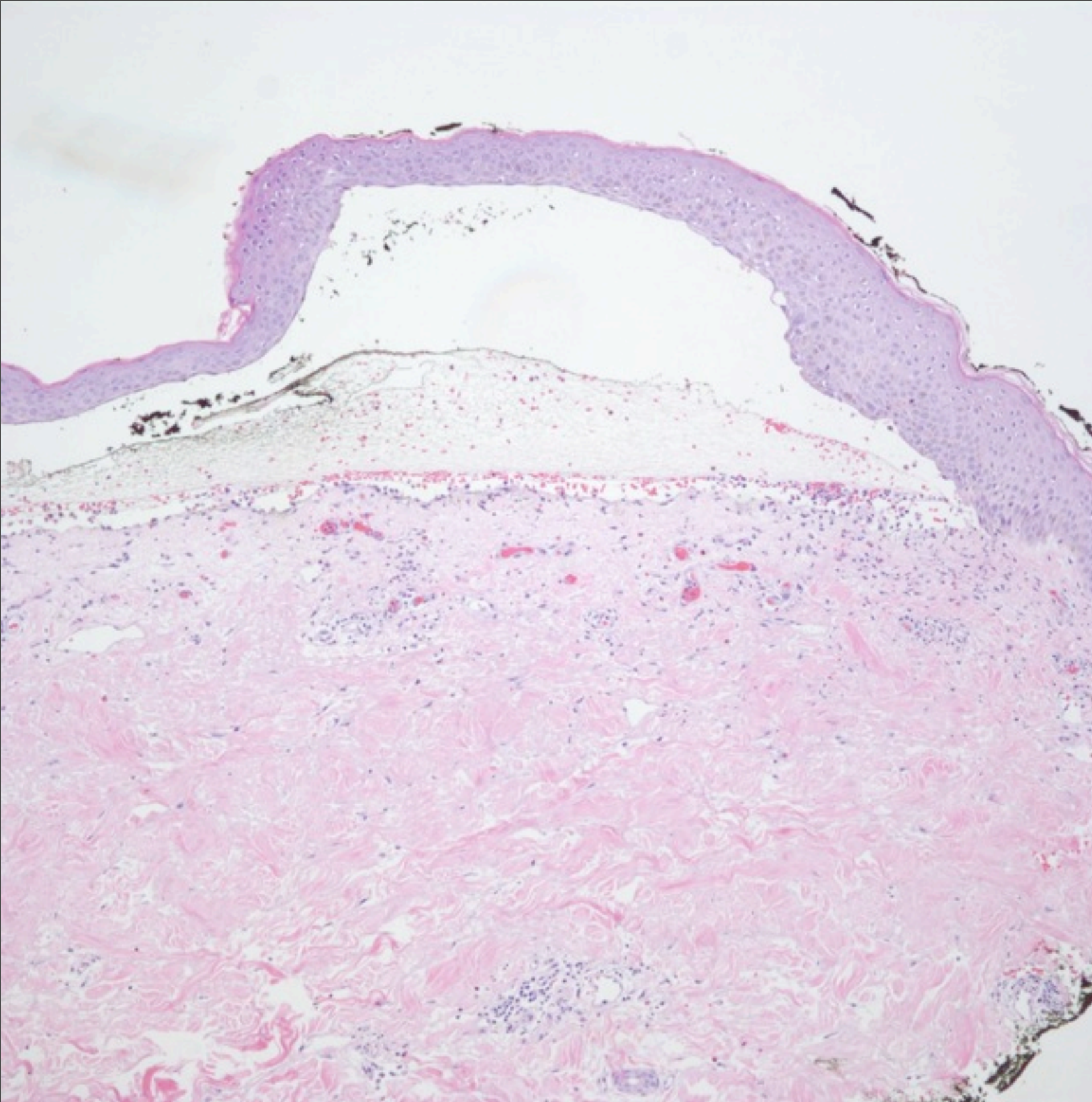




# Bullous Pemphigoid





No acantholysis

Eosinophils  
Predominate  
over PMNs

Subepidermal bullae